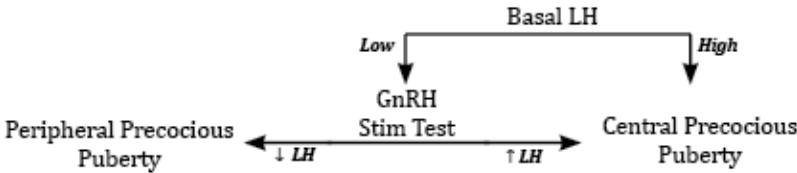


White Coat Companion 2019 Errata

Updated: 10/17/20

Page Number	Type (Date Added)	Location	Details
Cardiology			
Cards 1	Clarification (9/8/2020)	Asymptomatic CAD	Family history of premature CAD (< 55 M/ 65 F)
Cards 4	Error (9/8/2020)	Heart Failure	BNP: High sensitivity, high negative predictive value
Cards 14	Clarification (1/1/2020)	Mitral Stenosis	Surgery is the definitive management for MS, however medical therapy is often necessary to manage symptoms and comorbid conditions (HF, AF) Warfarin is the first line anticoagulant in mitral stenosis
Pulm/Crit			
Pulm 15	Clarification (1/1/2020)	Parapneumonic Effusions	Gram stain and culture can be positive up to ~ 50% of the time (in the book is listed as usually negative).
Renal			
Renal 2	Error (2/1/2020)	Hypertonic Hyponatremia	Hypertonic hyponatremia is typically caused by elevated glucose, sorbitol or mannitol. Ethylene glycol or methanol do not typically cause this (as indicated in WCC). In addition, the note regarding the osmotic gap is not relevant and can be crossed out.
Renal 17	Error (8/20/2020)	Nephrotic	Loss of anti- THROMBIN (not plasmin)
Renal 23	Update (6/4/2020)	ADPKD	Tolvaptan can be used in certain cases of ADPKD to help slow disease progression
Renal 23	Error (10/27/20)	ADPKD	PKD2 is on chromosome 4 (not 12)

Renal 24	Error (8/18/2020)	Calcium Phosphate	Risk factor is distal RTA (not proximal RTA) Thiazides are NOT a risk factor
Renal 24	Error (4/1/2020)	Uric Acid Stones	Urine pH is < 5.5 (not > 5.5 as stated). The urine pH on average for those with uric acid stones is 5.4. Acidic urine is correctly listed as a risk factor
Renal 24	Error (5/21/2020)	Cysteine Stones	Caused by cystinuria (not homocystinuria)
Endocrine			
Endo 16	Clarification (12/7/20)	Secondary Hyperparathyroid	PO4 is high with CKD, but LOW with vitamin D deficiency
Endo 29	Error (3/1/2020)	Precocious Puberty	Error in flowchart, with corrected one below. 
GI			
GI 12	Error (8/25/2020)	Pancreatic Insufficiency	Decreased fecal elastase (not increased)
GI 21	Error (7/14/2020)	Colon Cancer	Obstruction and hematochezia are more common with left-sided cancers, while iron deficiency anemia (from chronic, insidious bleeding) is more common with right sided lesions
GI 26	Clarification (7/22/20)	Hemorrhoids	Internal hemorrhoids are from the superior (internal) hemorrhoidal plexus, while external hemorrhoids are from inferior (external) hemorrhoidal plexus
GI 42	Update (3/1/2020)	Hepatitis C	Preferred treatment of acute hepatitis C is now with antivirals (rather than previous guidelines to monitor for spontaneous viral clearance before treatment)
GI 42	Update (8/16/20)	Hepatitis E	Previously classified as calcivirus, now is hepevirus

GI 43	Error (6/20/2020)	Hepatitis B	Chronic infection has positive HBsAg
GI 47	Update (3/1/2020)	C Diff Infection	For non-severe and severe C Diff, Fidaxomicin is the alternative agent to Vancomycin (not Metronidazole as listed)
Heme-Onc			
Rheum/MSK			
Rheum 31	Clarification (12/7/20)	Paronychia	Treatment is warm compresses, antibiotics reserved for severe cases
Rheum 35	Update (9/28/20)	Ankle Sprain	Grading Classifications: Grade I: Mild stretching Grade II: Incomplete tear Grade III: Complete tear
Rheum 36	Clarification	Upper trunk palsy	Presents with adduction/internal rotation of the arm, and IMPAIRED flexion /supination
Derm			
Derm 13	Error (4/1/2020)	Pemphigus vulgaris	Nikolsky sign often + (not negative as indicated)
Derm 22	Error (4/1/2020)	Androgenic alopecia	DHT is increased in this disorder (not decreased as indicated)
Derm 25	Error (7/22/2020)	Melanoma	Lymphatic mapping/lymph node biopsy is indicated if > 0.8 mm (not cm as noted)
ID			
ID 34	Clarification (12/7/20)	IRIS	Generally can initiate ART within 2 weeks of opportunistic infection. Delay > 2 weeks for TB or cryptococcus meningitis.
ID 42	Error (12/7/2020)	Rifampin	Is CYP inducer (not inhibitor)
Neurology			

Neuro 19	Error (4/1/2020)	Multiple Sclerosis	Definitions of primary and secondary progressive MS reversed. Should be: - Primary Progressive: Progressive accumulation of disability (temporary improvements or partial recoveries possible, but overall worsens) - Secondary Progressive: Initial relapse-remit, followed by progressive disease
Neuro 19	Error (4/1/2020)	Multiple Sclerosis	Visual evoked potentials show delayed P100 peak (not S100)
Primary Care/EM			
Psychiatry			
Psych 32	Clarification 5/1/2020	Benzodiazepine	Acute benzo intoxication can cause drowsiness, confusion, slurred speech, and ataxia. Respiratory depression usually only occurs if taken with a co-ingestant (like EtOH or opiates).
Psych 33	Error (4/1/2020)	Korsakoff Syndrome	Korsakoff syndrome is irreversible (not reversible). Features include amnesia and confabulation (not short term).
Pediatrics			
Surgery			
Surg 21	Error (7/8/2020)	Nitric Oxide	Nitrous oxide
OB-GYN			
OBGYN 1	Error (5/21/2020)	TPAL	T stands for Term, which is any baby born > 37 weeks (not 20 weeks) L stands for living children
OBGYN 4	Update (12/7/20)	Cell Free DNA	ACOG recommends cell free DNA as primary screening test for aneuploidy in 2021 guidelines
OBGYN 30	Error (10/16/2020)	First Stage	Should say "First Stage (Active)" [not passive] on row 3
OBGYN 39	Update (12/7/20)	Gestational Diabetes	Metformin can be used for management of diabetes that is not controlled with dietary modification alone

OB GYN 40	Update (12/7/20)	Preeclampsia	Aspirin can be used for prophylaxis in high risk patients
OBGYN 65	Update (12/7/20)	Trichomonas Treatment	Metronidazole course now recommended to be 1 week (compared to single dose)